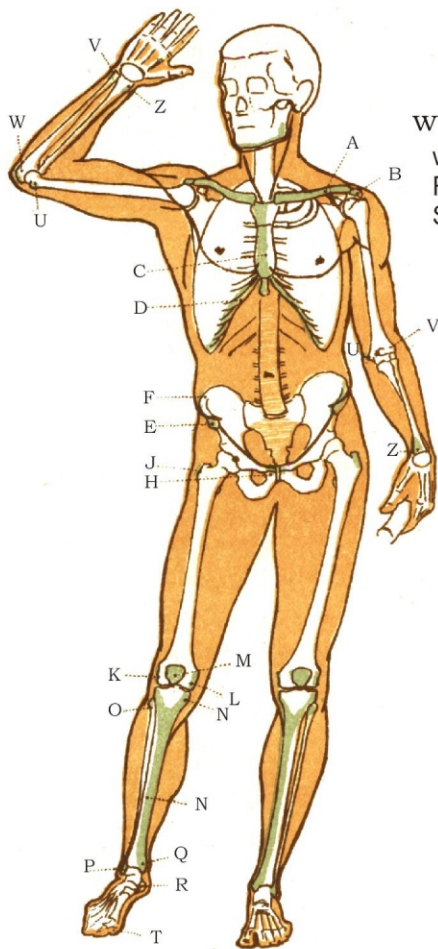


# Anatomical Reference For The Artist

Copyright 2010  
 www.AnatomicalPrints.com  
 www.DCFirst.com Chiropractic  
 Resources for Doctors,  
 Students and Patients.



## Bones Reference

### Trunk

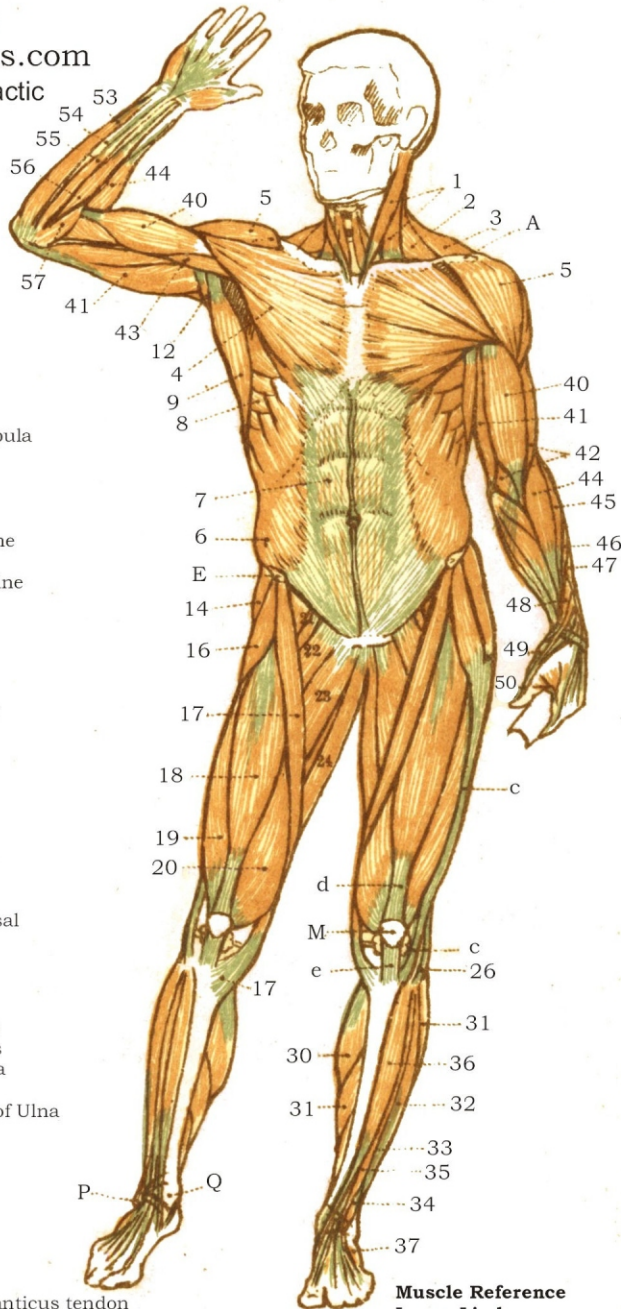
- A. Clavicle
- B. Acromium process of Scapula
- B'. Spine of Scapula
- B". Base of Scapula
- C. Sternum
- D. Cartilages of the Ribs
- E. Anterior superior iliac spine
- F. Iliac crest
- G. Posterior superior iliac spine
- H. Pubis
- I. Sacrum

### Lower Limb

- J. Great trochanter of Femur
- K. Outer condyle of Femur
- L. Inner condyle of Femur
- M. Patella
- N. Head of Tibia
- N'. Shaft of Tibia
- O. Head of Fibula
- P. Outer malleolus of Fibula
- Q. Inner malleolus of Tibia
- R. Os Calcis
- S. Tuberosity of 5th metatarsal
- T. Ball of great toe

### Upper Limb

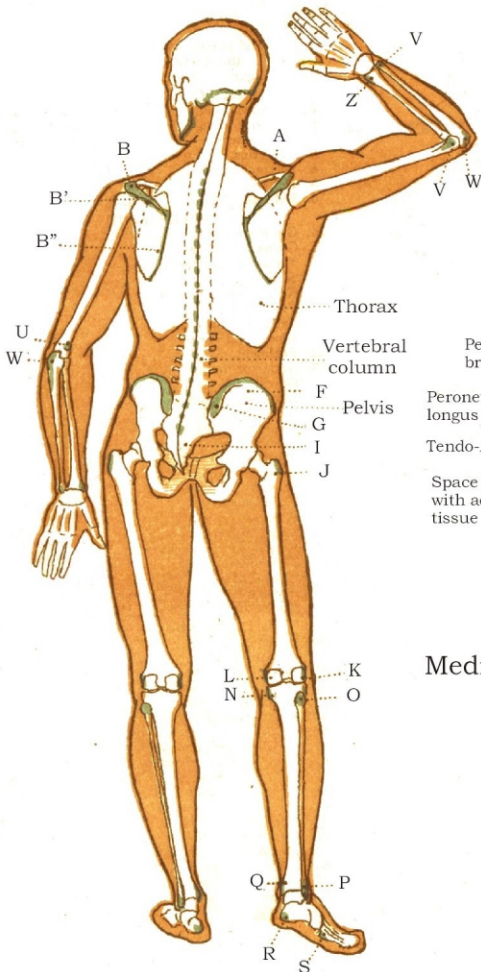
- U. Inner condyle of Humerus
- V. Outer condyle of Humerus
- W. Olecranon process of Ulna
- X. Posterior border of Ulna
- Y. Head and styloid process of Ulna
- Z. Styloid process of Radius



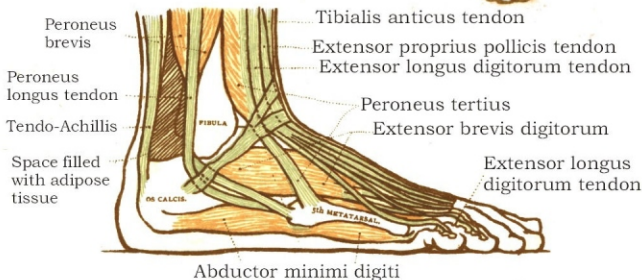
## Muscle Reference

### Lower Limb

- 14. Gluteus medius
- 15. Gluteus maximus
- 16. Tensor fasciae femoris
- 17. Sartorius
- 18. Rectus femoris
- 19. Vastus externus
- 20. Vastus internus
- 21. Iliacus and Psoas
- 22. Pectineus
- 23. Adductor longus
- 24. Gracilis
- 25. Adductor magnus
- 26. Biceps femoris
- 27. Semitendinosus
- 28. Semimembranosus
- 29. Plantaris
- 30. Gastrocnemius
- 31. Soleus
- 32. Peroneus longus
- 33. Peroneus brevis
- 34. Peroneus tertius
- 35. Extensor longus digitorum
- 36. Tibialis anticus
- 37. Extensor brevis digitorum
- 38. Abductor minimi digiti
- 39. Abductor pollicis



## Lateral View of Foot



## Medial View of Foot

